



Experience Anatomy

WHERE EDUCATION MEETS APPLICATION

S a m p l e

*Cardiovascular
System*

Table of Contents

Page 3 – Halved Heart

Page 4 – Halved Heart – Internal Anterior View

Page 5 – Halved Heart – Vasculature

Page 6 – Halved Heart – Electrical System

Page 7 – Whole Heart

Page 8 – Whole Heart – Anterior Vasculature

Page 9 – Whole Heart – Posterior Vasculature

Page 10 – Whole Heart – Superioposterior Vasculature

Page 11 – Whole Heart – Blood Flow through the heart

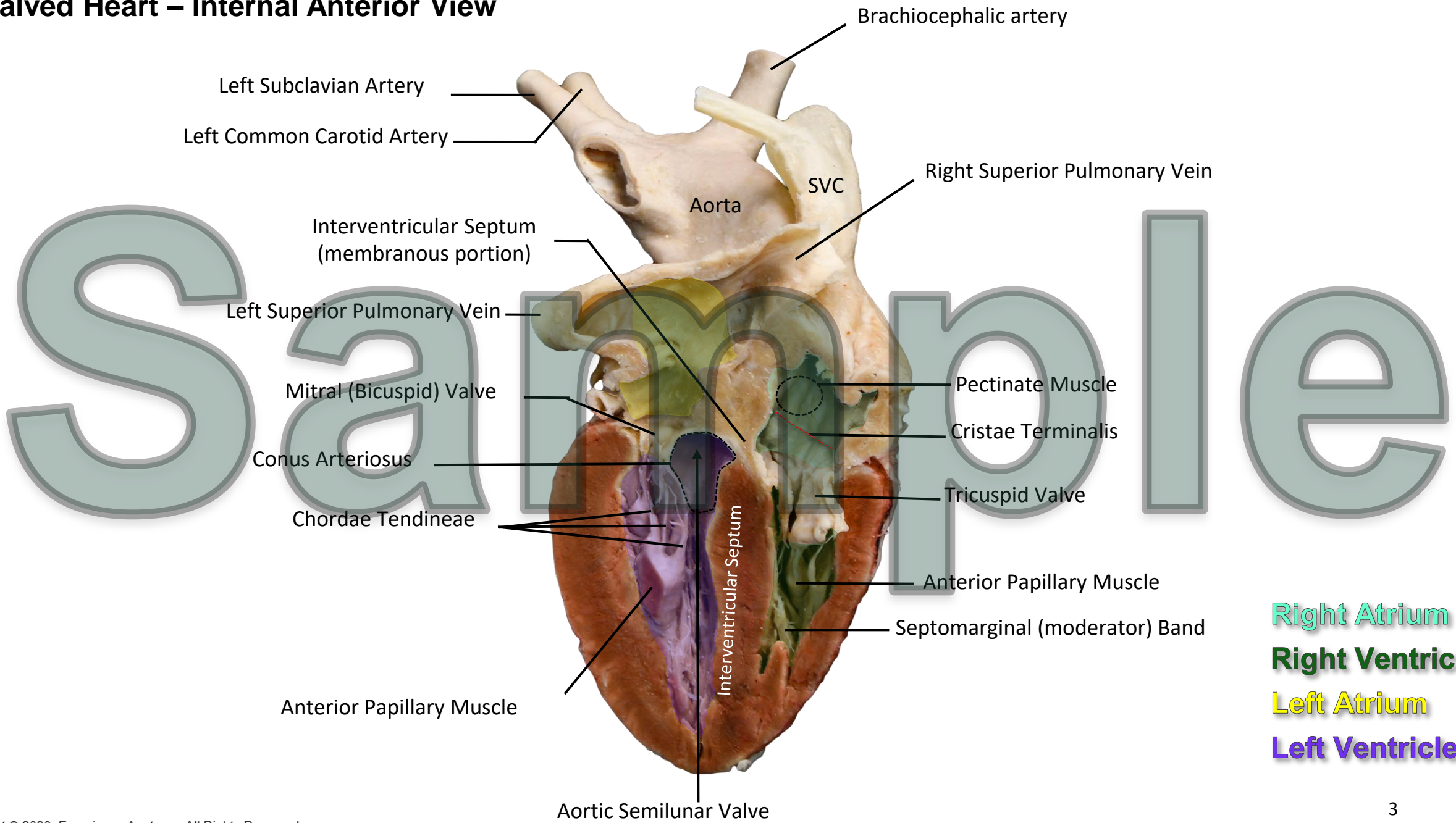
Page 12 – Spleen

Page 13 – Blood Vessels of Foot

Sample

*****Sample does not include all pages provided in the full identification guide**

Halved Heart – Internal Anterior View

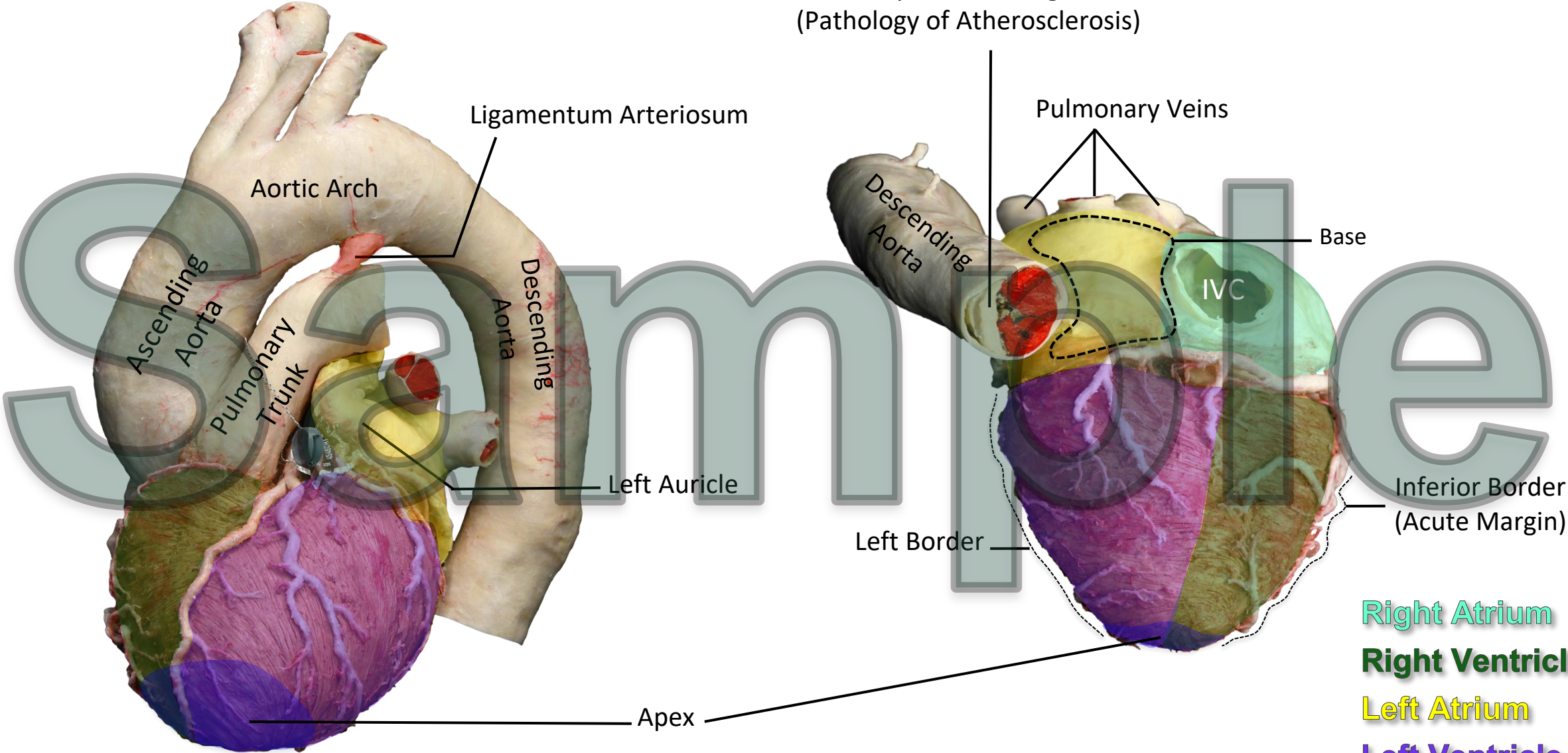


- Brachiocephalic artery
- Left Subclavian Artery
- Left Common Carotid Artery
- SVC
- Right Superior Pulmonary Vein
- Aorta
- Interventricular Septum (membranous portion)
- Left Superior Pulmonary Vein
- Mitral (Bicuspid) Valve
- Conus Arteriosus
- Chordae Tendineae
- Interventricular Septum
- Pectinate Muscle
- Cristae Terminalis
- Tricuspid Valve
- Anterior Papillary Muscle
- Septomarginal (moderator) Band
- Anterior Papillary Muscle
- Aortic Semilunar Valve

Right Atrium
Right Ventricle
Left Atrium
Left Ventricle

Whole Heart

Aortic Plaque and Enlarged Aorta
(Pathology of Atherosclerosis)



- Right Atrium
- Right Ventricle
- Left Atrium
- Left Ventricle

Whole Heart – Anterior Vasculature

